

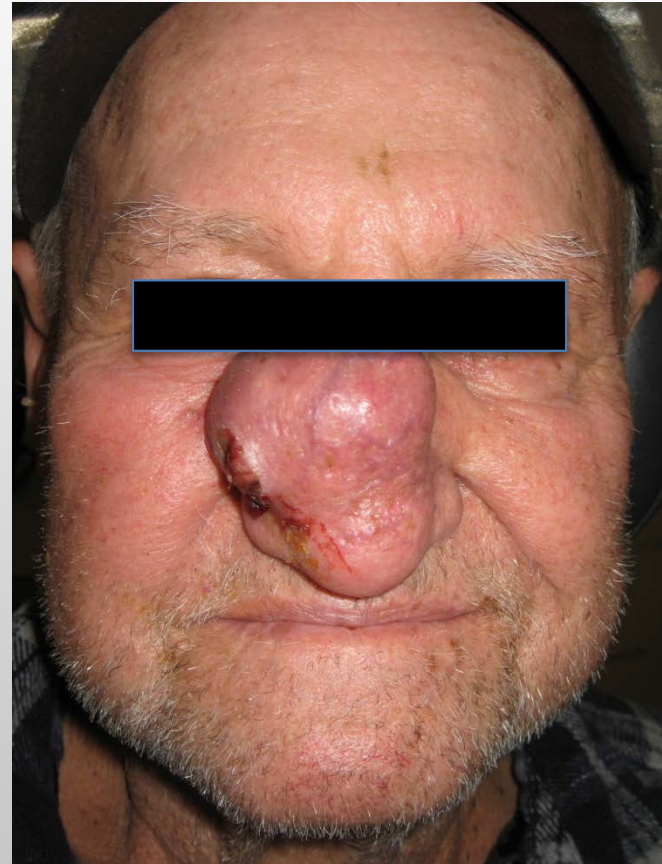Making Cancer History®

Surgery and Neoadjuvant Treatments for Cutaneous SCC

Neil D. Gross, MD
Professor, Head and Neck Surgery

Cutaneous SCC

- Increasing incidence
- Surgery +/- radiation therapy
- Highly morbid



Neoadjuvant Immunotherapy for CSCC

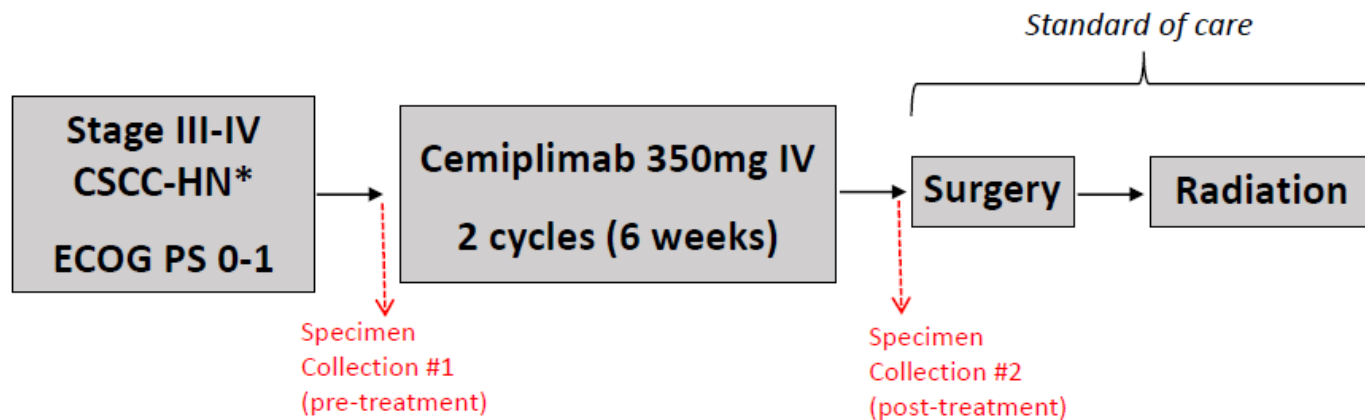
Study Design

Single institution

Open-label, non-randomized

Window-of-opportunity

N=20



Neoadjuvant Immunotherapy for CSCC

Inclusion Criteria

1. Primary or recurrent, advanced-stage (III/IV) cSCC
2. Surgery and radiation planned with curative intent
3. Measurable disease ($>1.5\text{cm}$) per RECIST 1.1

Neoadjuvant Immunotherapy for CSCC

Outcome Measures

Primary:

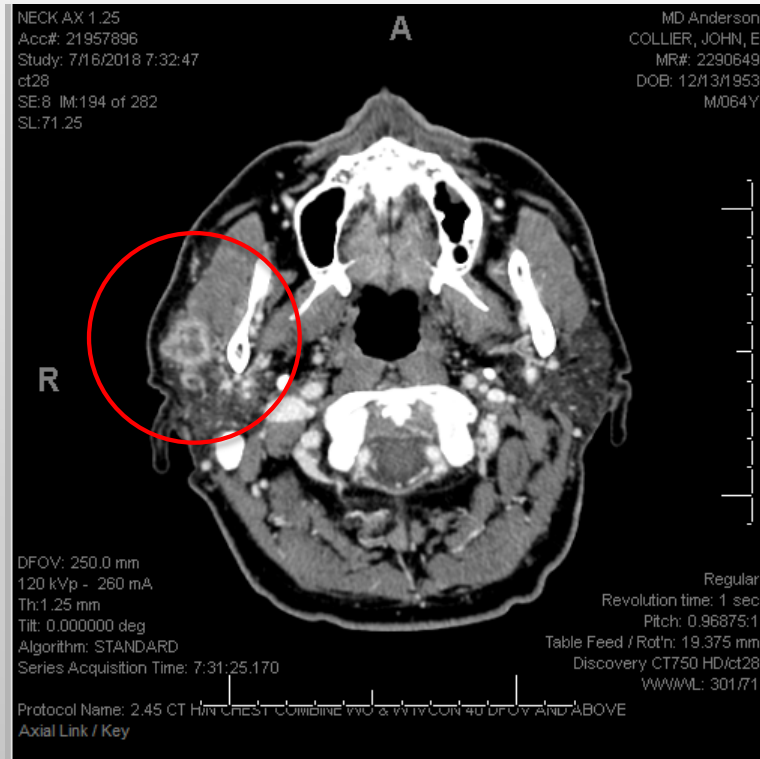
- ORR using RECIST v1.1

Secondary:

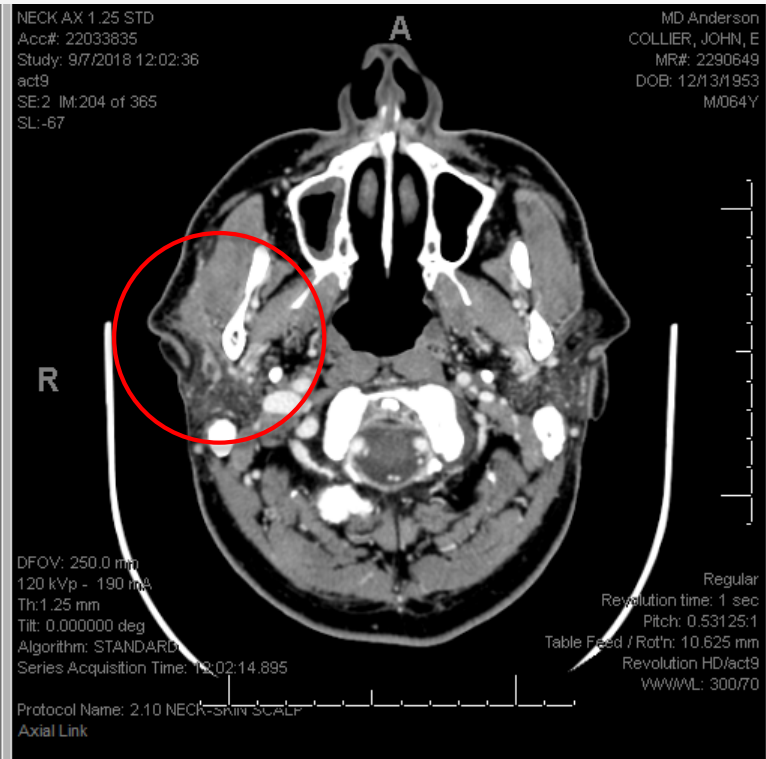
- Safety and tolerability
- Pathologic response rate, time to recurrence and patterns of failure
- 2-year DSS, DFS, OS (compared to historical)
- **Correlatives**

Neoadjuvant Immunotherapy for CSCC

Patient #2



Pre



Post

Neoadjuvant Immunotherapy for CSCC

Patient #2

DIAGNOSIS

A. RIGHT SUPERFICIAL PAROTID:

Salivary gland with fibrosis, negative for residual tumor (s/p neoadjuvant therapy)
Eleven lymph nodes, negative for tumor (0/11)

B. RIGHT NECK DISSECTION LEVEL IIB:

Four lymph nodes and salivary tissue, negative for tumor (0/4)

C. RIGHT NECK DISSECTION LEVEL IIA:

Four lymph nodes, negative for tumor (0/4)

D. RIGHT NECK DISSECTION LEVELS III AND IV:

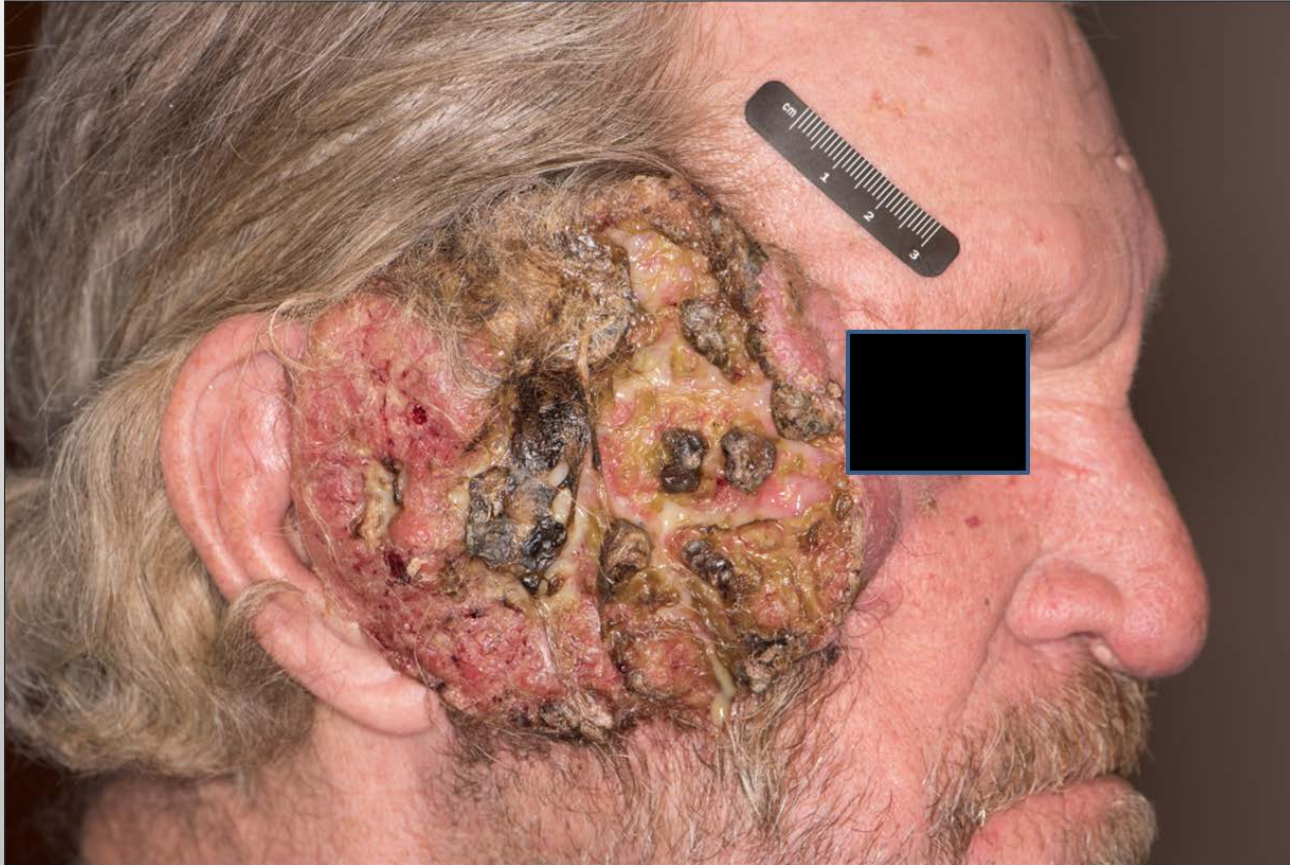Six lymph nodes, negative for tumor (0/6)

E. RIGHT TISSUE OVER UPPER DIVISION NERVE:

Salivary tissue, negative for tumor

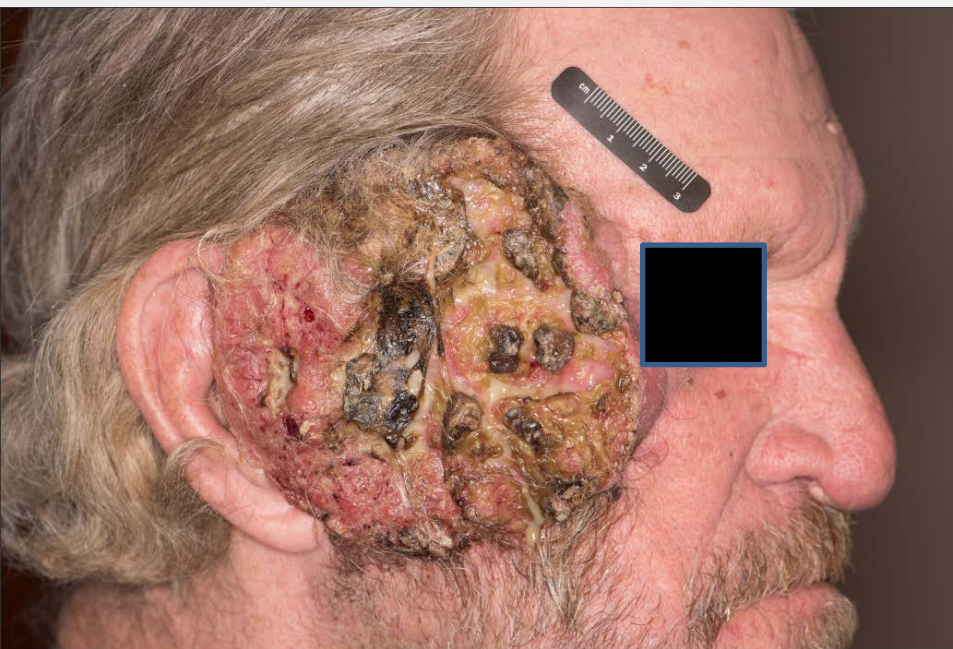Neoadjuvant Immunotherapy for CSCC

Patient #5

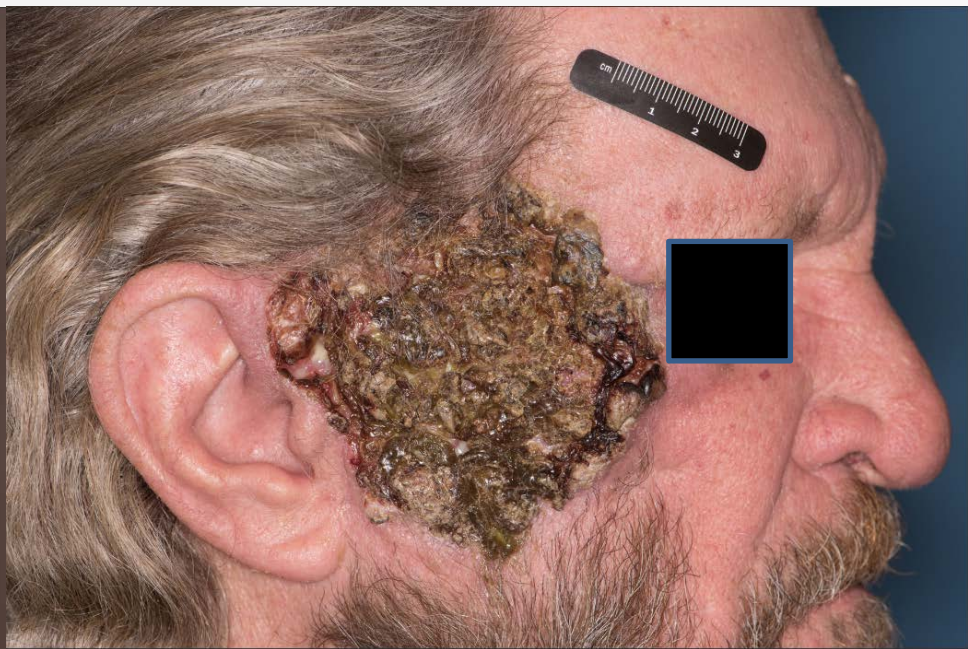

Neoadjuvant Immunotherapy for CSCC

Patient #5



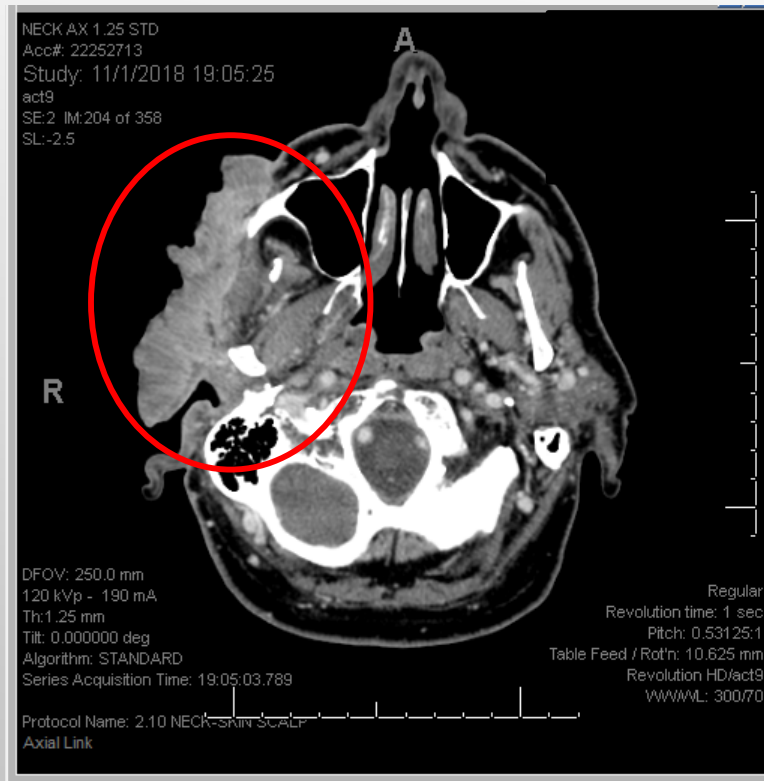
PRE



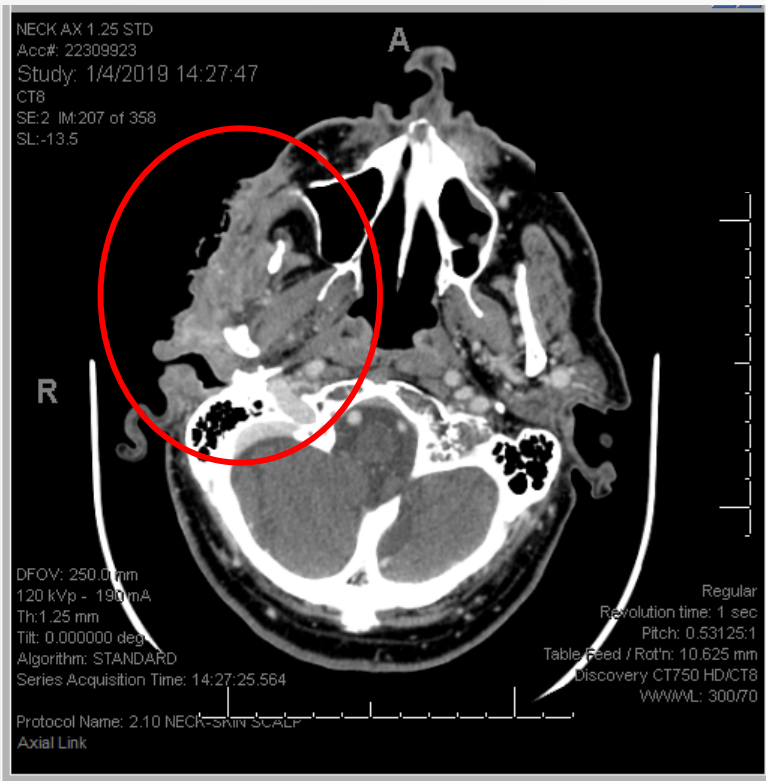
POST

Neoadjuvant Immunotherapy for CSCC

Patient #5



PRE



POST

Neoadjuvant Immunotherapy for CSCC

Patient #5

Procedure: Composite right ear resection, right parotidectomy, right partial temporal bone resection, and right neck dissection

Tumor Site: Periauricular skin

Tumor Laterality: Right

Tumor Focality: Unifocal

Tumor Size

Greatest dimension (in centimeters): residual 0.6 cm (post-treatment)

Tumor Depth of Invasion (DOI): N/A

Histologic Type: squamous carcinoma

Specimen Margins: Uninvolved by invasive tumor

Lymphovascular Invasion: Not identified

Perineural Invasion: Not identified

Regional Lymph Nodes: Assessed

Number of Lymph Nodes Involved: 0

Number of Lymph Nodes Examined: 76

Pathologic Stage Classification (pTNM, AJCC 8th Edition)

Primary Tumor (pT): ypT1

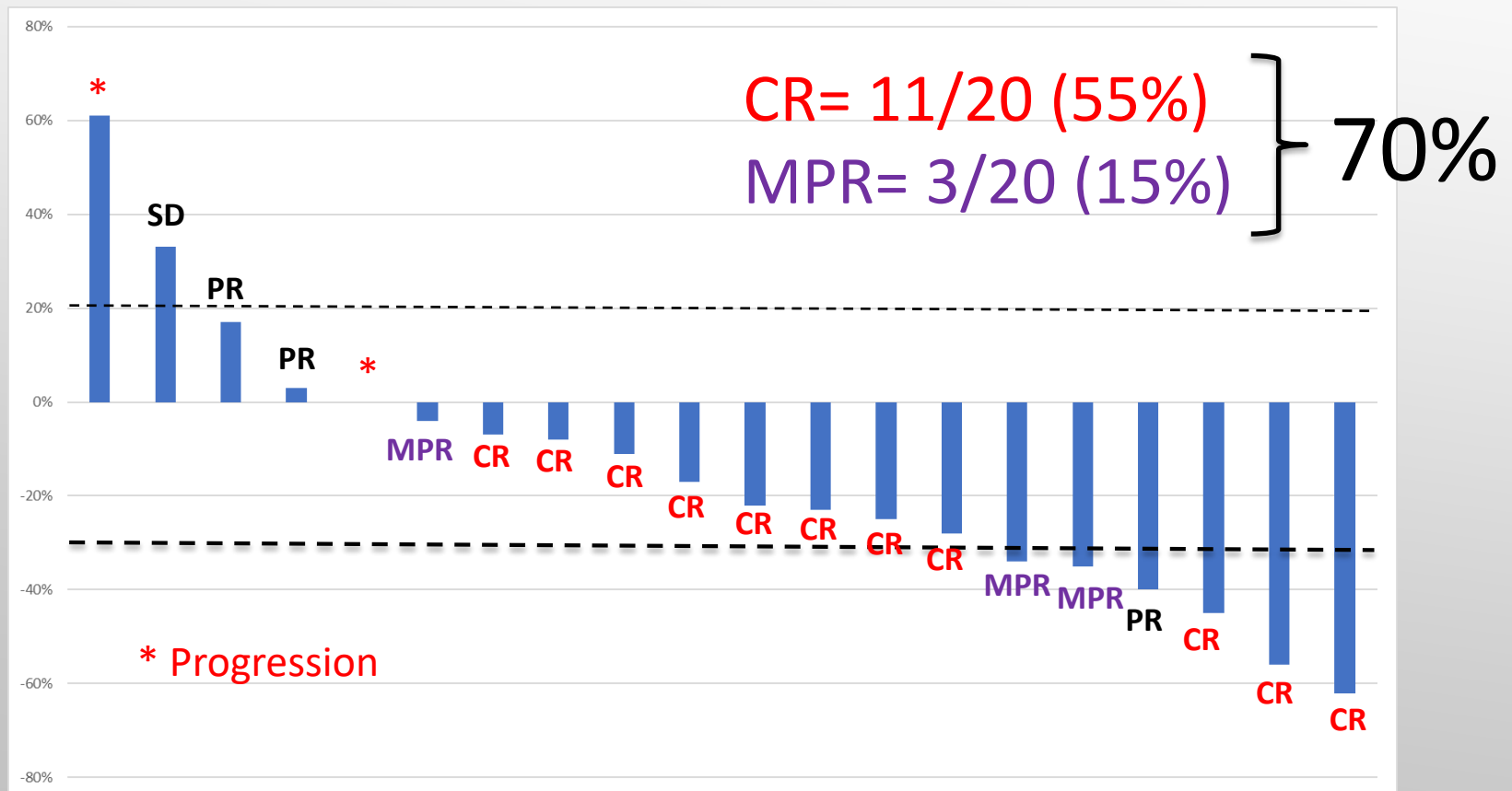
Regional Lymph Nodes (pN): ypN0

Distant Metastasis (pM): NA

Neoadjuvant Immunotherapy for CSCC

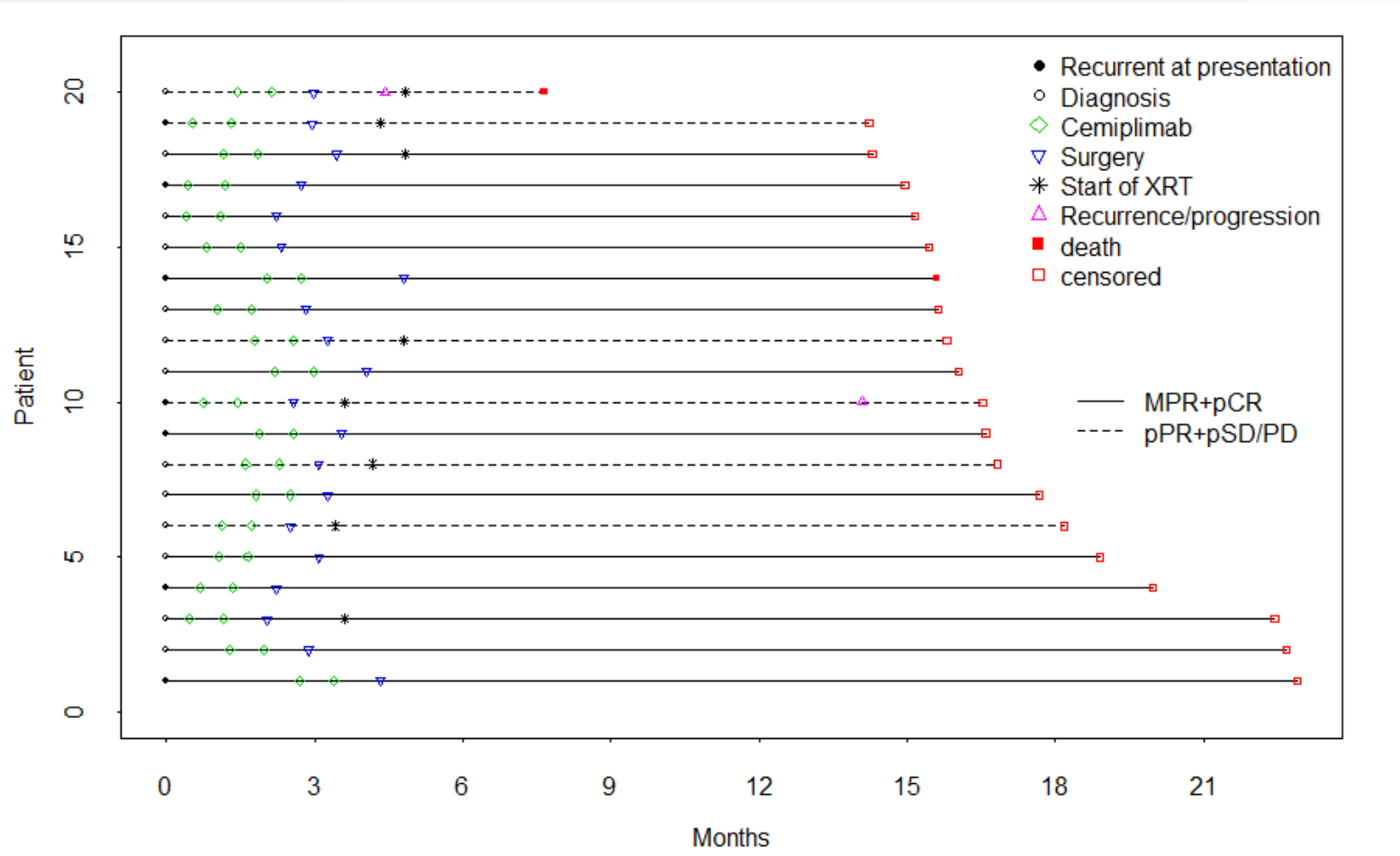
Results

RECIST 1.1



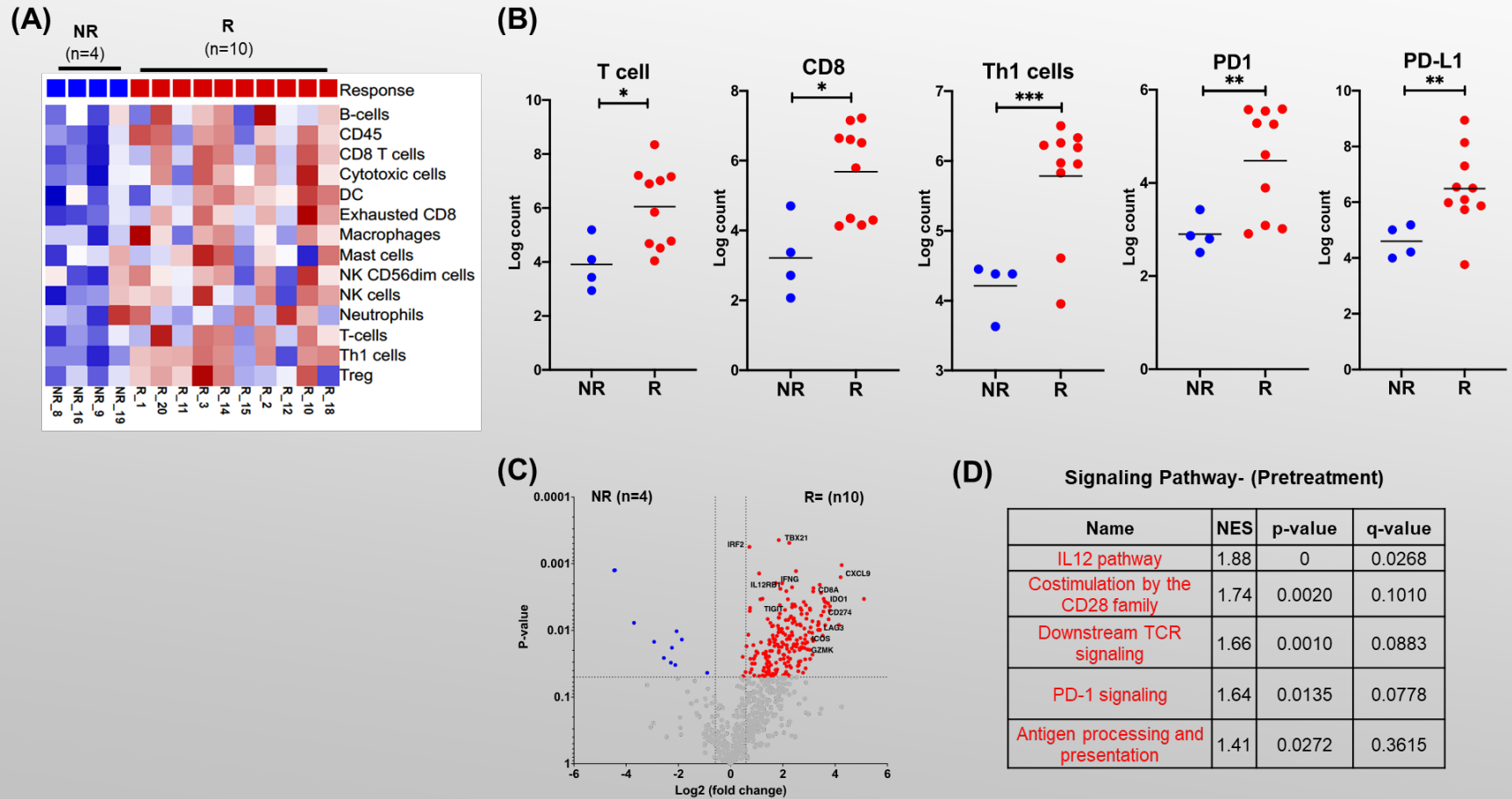
Neoadjuvant Immunotherapy for CSCC

Results



Neoadjuvant Immunotherapy for CSCC

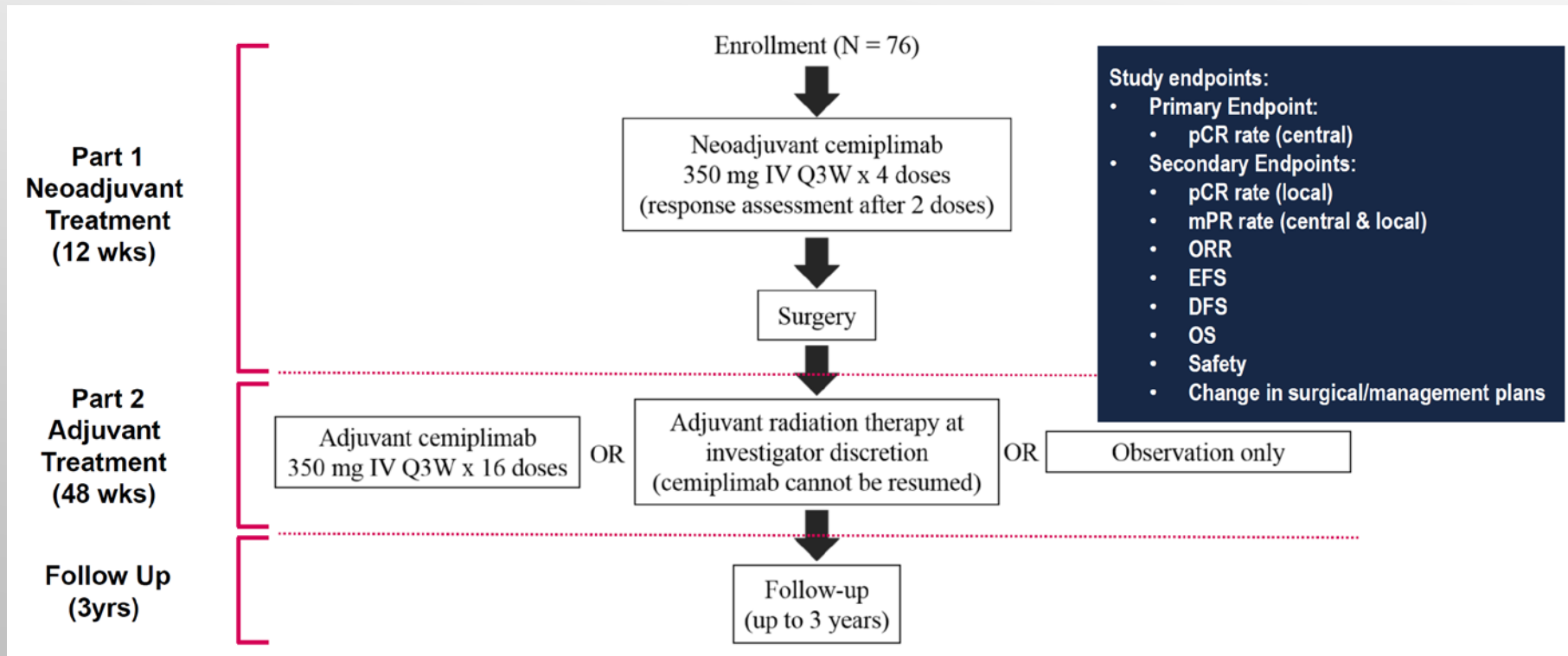
Correlative Studies



Neoadjuvant Immunotherapy for CSCC

Next Steps

Confirmatory multicenter trial



Questions

ngross@mdanderson.org



@DrNeilGross



~~Cancer~~[®]